

Vitrectomy with the horse.

Friday 10 December 2004 / 15.10 hrs.

József Tóth

Tierklinik Hochmoor, Gescher-Hochmoor, Germany

Email: info@tierklinik-hochmoor.de

Uveitis rezidiva equi (ERU = Equine Recurrent Uveitis) is the most common inflammatory change to the uvea of the horse, it can affect up to 12% of the total population. On a global basis, ERU is the main cause for the blinding of horses. ERU is caused by a persisting intra-ocular leptospirosis. The uveitis attacks continue for as long as indications to an intra-ocular leptospirosis are identifiable. ERU is a contagious disease, in the course of which temporarily overshooting auto-immune reactions occur (Wollanke et al, 2004).

More than fifteen years ago, vitrectomy was introduced into equine medicine for the treatment of recurrent uveitis (Werry and Gerhards, 1989). The pars plana vitrectomy is meant to remove inflammatory exudates and inflammatory mediators, inflammatory products and Leptospira bacteria. Uveitis attacks should be effectively prevented through vitrectomy and simultaneous elimination of the intra-ocular leptospirosis.

Today, we have an extended indication for vitrectomy. Indications for the surgical exchange of vitreous humour in the area of the anterior eye segment are:

- Injuries (haemorrhages)
- Membranes in the area of the pupillary plane

Indications in the area of the posterior eye segment are:

- ERU
- Uveitis
- Membranes
- Haemorrhages

Before the vitrectomy, a thorough examination is carried out (direct ophthalmoscopy, slit lamp examination, ultrasonic examination). Nowadays, the ultrasonic examination of the horse's eye has become routine with opaque optical media. The ophthalmosonography provides images of excellent quality of the healthy and pathologically altered eye to the examiner.

The vitrectomy technique: a sclerotomy is carried out to a length of 3mm under a conjunctival flap 12-14mm behind the limbus in the dorsal area. A vitrectomy tool is pushed into the vitreous body cavity and a vitrectomy carried out, which is as comprehensive as possible, with transcorneal visual control.




Figure 1: Handpiece of the vitrectoms by "Erbe"

The removed vitreous volume is replaced by a special saline solution (BSS). After the completed vitrectomy, the sclera and conjunctiva wounds are closed. The post-operative treatment consists of local adrenocortical steroid, gentamicin and atropine doses.

The recurrent inflammation of the eye should be prevented, for the most part, through the surgical exchange of vitreous humour. A normal visual acuity and normal sight are strived for as the optimum objective.

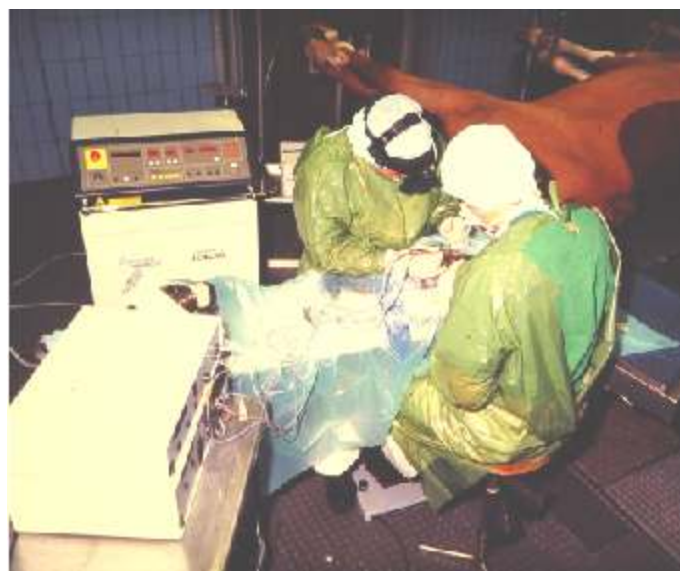

Figure 2: General view at the vitrectomy

So far, 416 eyes have been operated on. The absence of recidivity was 95.3% according to information from owners and according to the figures of the domestic animal veterinarians. After a vitrectomy, we had to remove 8 eyes due to an intense and treatment-resistant recurrence and one eye due to a panophthalmitis (2.1%).

Mild uveitis attacks and a superficial keratitis occurred in 11 cases (2.6%). A retinal detachment occurred in 3 cases (0.7%). Surprisingly, only 2 eyes (0.4 %) were blind as a result of a secondary cataract.

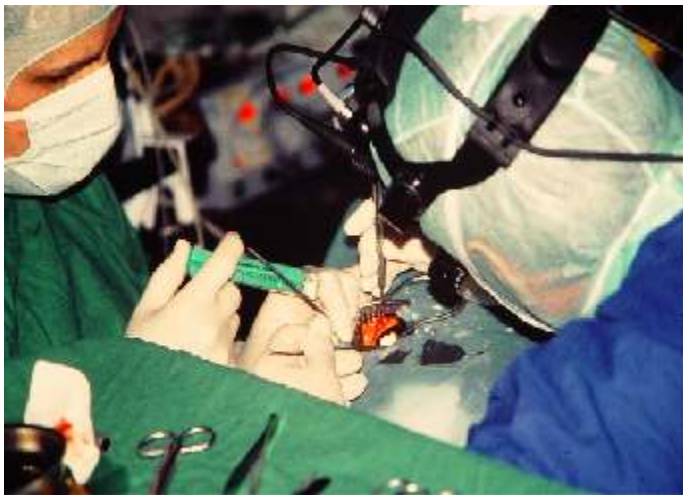

Figure 3: Situation during vitrectomy surgery

In some cases, however, you have to settle for keeping the seriously affected eye without it being possible to restore vision again. The request is often put forward to the veterinarian not to remove the eyeball for cosmetic reasons. To this group belong horses with reduced intra-ocular pressure (phthisis of the eyeball) and horses with raised intra-ocular pressure (secondary glaucoma).

According to our experience, one can achieve positive results with the vitrectomy in many of these cases. The eyes look barely changed for the owner and are painless for the animals.

The progression of an atrophy can be prevented and the intra-ocular pressure considerably reduced in the case of glaucoma. We have operated on 17 considerably damaged eyes. The eyes were 8-16mm smaller than the partner eye. The intra-ocular pressure was measured lower with a Tonopen. After vitrectomy, we had to remove 3 eyes (17%).

The remaining 14 eyes showed a better intra-ocular pressure after the operation. Several weeks after the operation, a superficial keratitis developed with two patients.

Two patients were vitrectomised with glaucoma. Glaucoma with the horse is generally a secondary glaucoma after uveitis. However, uveitis leading to a glaucoma should be distinguished from ERU. In advanced stages of the disease, the differentiation is easier, as the eyeball gradually becomes bigger with glaucoma in contrast to eyes affected by ERU. In addition, ligament cloudiness and temporary or permanent corneal oedemas are evident.

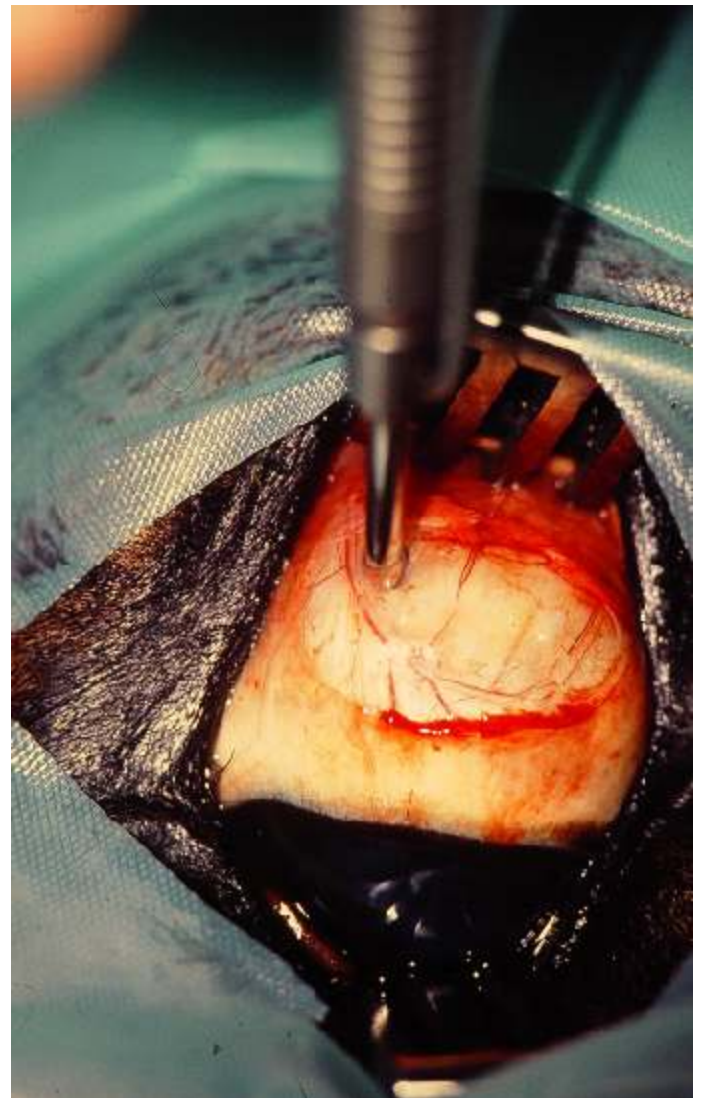

Figure 4: Incision for entering the pars plane vitrectomy



Case 1

8-year-old crossbreed, gelding, 5 years ago the right eye was inflamed again and again and was treated by several veterinary surgeons. After an intense inflammatory process, finally a dislocation of the lens was carried out with this horse.

The dislocated lens was removed by a human ophthalmologist. The eye still did not settle down after that and was inflamed again and again. In the examination of the right eyeball, this was bigger (46.7mm), the cornea dull and barely transparent. The intra-ocular pressure amounted to 56 mmHg. Episclerally, one could detect a ciliary (hair-like) pannus.

After several treatments, we attained an inflammation-free period and performed a vitrectomy. The eye diameter had reduced to 41.2mm and the intra-ocular pressure to 29 mmHg 3 weeks after the operation. The cornea was clear and transparent, cosmetically beautiful. The owner is still very satisfied three years after the vitrectomy.

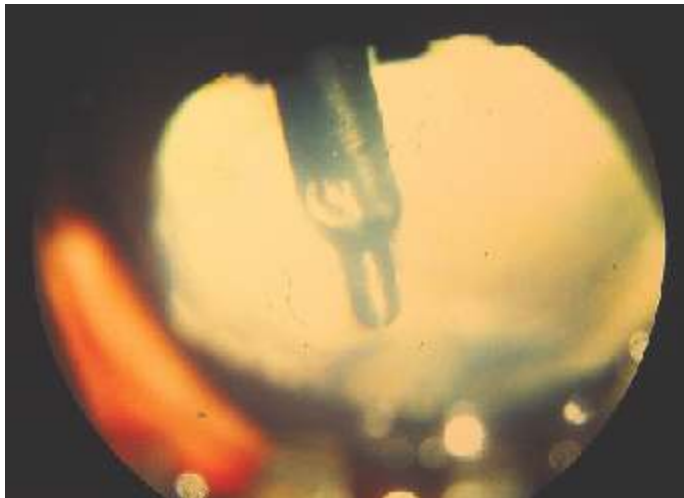


Figure 5: Position of the vitrectom in the corpus vitreum

Case 2

18-year-old crossbreed, mare. Before the horse was examined, the eye went dull with streaks again and again for four months and then the whole eye became milky and dull. There is a milky cornea with several streaks during the examination of the horse. The eyeball diameter amounts to 44.7mm, the intra-ocular pressure 74 mmHg.

After preliminary treatment, a vitrectomy was performed and many floating membranes removed in the process. The eye diameter had reduced to 43.1mm and the pressure had fallen to 34 mmHg, 3 weeks after the operation. The cornea is now clear and transparent. According to our findings, we were able to positively influence the course of the disease through a vitrectomy with both eyes affected by glaucoma.

A further indication for the use of vitrectomy is the opacity of the vitreous body of unknown genesis in high performance horses. According to a preliminary report, the horses show nervousness and uncertainty, indications of inflammation are lacking. So far, we have vitrectomised two horses on both sides. After the vitrectomy, both horses are victorious in sport; afterwards uncertainty and nervousness no longer arise.

